


**12**

**AUTOPSY REPORT**

No. 2017-07309  
YODER, BOAZ

I performed an autopsy on the body of 

at THE DEPARTMENT OF MEDICAL EXAMINER-CORONER

Los Angeles, California on October 7, 2017 9:00 hours  
(Date) (Time)

From the anatomic findings and pertinent history I ascribe the death to:

(A) Asphyxia

DUE TO OR AS A CONSEQUENCE OF

(B)

DUE TO OR AS A CONSEQUENCE OF

(C)

DUE TO OR AS A CONSEQUENCE OF

(D)

OTHER CONDITIONS CONTRIBUTING BUT NOT RELATED TO THE IMMEDIATE CAUSE OF DEATH:

Methamphetamine exposure (breastfeeding)

*Anatomical Summary:*

I. Asphyxia

A. 25-day-old male infant found unresponsive in crib after mother laid excessive blankets on him to keep him warm

1. Petechiae on heart
2. Mild pulmonary edema and congestion, combined weight 120.6 grams

B. Post mortem toxicology detected methamphetamine (breastfeeding)

II. Healing burn on the left hand (1.7 x 1 cm)

**CIRCUMSTANCES:**

Please see Investigator's Report.

**EXTERNAL EXAMINATION:**

The body is that of a well-developed male infant without dysmorphic features and 25 days of age, who weighs 4,300 grams or 9.5 pounds (approximately 50<sup>th</sup> percentile for age) and has a length of 52.2 cm (approximately 50<sup>th</sup> percentile for age), a head circumference of 35 cm (approximately 10<sup>th</sup> percentile for age), a chest circumference of 36 cm, and an abdominal circumference of 38 cm.

The body is cool to the touch. Rigor mortis is absent. Livor mortis is present on the face, neck, upper chest, back and posterior legs.

The head is normally formed. There is brown hair that measures 4 cm in length. The anterior fontanelle is patent and open; the

# 12

## AUTOPSY REPORT

No. 2017-07309  
YODER, BOAZ

Page 2

posterior fontanelle is closed. The eyes are normally formed. The pupils are round; the irides are brown. The corneas are translucent. The sclerae are white, and the conjunctivae are clear. No petechial hemorrhages are identified on the sclerae, bulbar conjunctivae, facial skin, or oral mucosa. The ears are normally formed and normally placed, with the appropriate amount of cartilage. The nose is unremarkable. The choanae are probe patent. The frenulum is intact. The tongue is normal in size. The palate is intact and normally arched. The mouth is edentulous, in keeping with the age of the infant. The mandible is normally formed.

The thorax is symmetric and the nipples normally formed and positioned. The abdomen is unremarkable. The anus is patent and free of lesions. The spine is normally formed without dimples or abnormal hair distribution.

The external genitalia are those of a normal male infant.

The extremities and digits are normally formed and symmetrical, without absence of digits.

No identifying marks or scars are readily apparent.

### **CLOTHING:**

The body was not clothed, and the clothing was not available for examination at the time of autopsy.

### **EVIDENCE OF THERAPEUTIC INTERVENTION:**

There is no evidence of therapeutic intervention or post mortem intervention for organ procurement.

### **POST MORTEM CHANGES:**

There is no postmortem change.

### **EVIDENCE OF TRAUMATIC INJURY (EXTERNAL/INTERNAL):**

On the dorsum of the left hand is a 1.7 x 1 cm irregularly shaped, red to yellow, healing burn.

**INTERNAL EXAMINATION****INITIAL INCISION AND CHEST/ABDOMINAL CAVITY:**

The body cavities are entered through the standard coronal incision and the standard Y-shaped incision. No adhesions or effusions are present in the pleural and peritoneal cavities. All body organs are present in normal and anatomic position. Serous surfaces are smooth and glistening. An intact diaphragm separates the thoracic and peritoneal cavities. Letulle technique of dissection is performed.

**SYSTEMIC AND ORGAN REVIEW:**

Note: The following observations are limited to findings other than injuries, if described above. Expected mean visceral weights for an infant of one month old are cited in parentheses following measured weights.

**NECK:**

The neck organs are removed en bloc with the tongue. Examination of the soft tissues of the neck, including strap muscles and large vessels, reveals no abnormalities. The hyoid bone and larynx are intact. The epiglottis is firm, non-swollen, and non-erythematous.

**MUSCULOSKELETAL SYSTEM:**

The axial and appendicular skeleton is unremarkable. The musculature is well developed and symmetrical. The color and consistency of skeletal muscle, soft tissues, and bone are normal. The diaphragm is normally formed with central membranous and peripheral muscular portions.

**CARDIOVASCULAR SYSTEM:**

The heart weighs 22.9 grams (20 grams); the shape and size of the heart are not unusual with appropriate lateralization features. The pericardial surfaces are smooth, glistening, and

unremarkable. The pericardial sac is free of significant fluid or adhesions. A few epicardial petechiae are noted between the aortic trunk and the left atrial appendage. The coronary arteries arise normally and follow the usual distribution of right dominance. The chambers are non-dilated and have the usual size and position relationships. The right ventricle is 0.3 cm in thickness, the interventricular septum is 0.7 cm in thickness, and left ventricle is 0.5 cm in thickness. The cardiac valve cusps and leaflets are thin, delicate, and normally formed without vegetations. The circumference of the cardiac valves is as follows: tricuspid valve 3.5 cm, mitral valve 3.5 cm, pulmonary valve 2.5 and aortic valve 2.5. The myocardium is homogeneously dark red-brown, firm, and unremarkable; the atrial and ventricular septa are intact. The endocardium is free of fibrosis. The foramen ovale is membrane covered. The pulmonary artery, the aorta, and their major branches arise normally and follow the usual course without thrombotic obstruction or coarctation. The ductus arteriosus cannot be probed. The vena cava, its major tributaries, and the pulmonary veins are patent and return to the heart in the usual distribution.

**RESPIRATORY SYSTEM:**

The heavy right and left lungs weigh 64.7 grams and 55.9 grams (58 grams, combined) respectively, with the normal distribution of lobes and fissures. The upper and lower airways are patent, and the mucosal surfaces are smooth and yellow-tan and without erythema. There is pink serous fluid within the airways. The pleural surfaces are smooth, glistening and have multifocal dark red areas. The pulmonary parenchyma is red-purple, and the cut surfaces exude small amounts of blood and frothy fluid. The pulmonary arteries are normally developed and patent.

**GASTROINTESTINAL SYSTEM:**

The esophagus courses to the stomach without fistulae and is lined by gray-white mucosa without lesions. The gastric mucosa has lost the usual rugal folds, and the lumen contains less than 5 mL of milky fluid. The pylorus is widely patent and without

muscular hypertrophy. The mesentery and the small and large bowel have the usual size/position relationship. The appendix is fixed in the right lower quadrant of the abdomen. The small intestine are of appropriate caliber without interruption of luminal continuity. The large bowel is mildly dilated in caliber and the mucosa is without erythema or necrosis. The serosa is smooth and glistening. The pancreas has normal, tan, lobulated parenchyma.

**HEPATOBIILIARY SYSTEM:**

The 192 gram liver (127 grams) has a normal configuration. The hepatic capsule is smooth, glistening, and intact, covering red-brown parenchyma with no significant fatty change. The central hepatic vasculature is free of thrombus. The gallbladder is normal, and the cystic duct is patent. On cut section, the biliary system is not prominent or cystic.

**URINARY SYSTEM:**

The right and left kidneys weigh 10.6 grams and 10 grams (32 grams, combined), respectively. The cortical surfaces are lobulated and red-brown. The cortices are well delineated from the medullary pyramids. The calyces, pelves, and ureters are free of dilatation. The urinary bladder is empty; the mucosa is tan and smooth.

**GENITAL SYSTEM:**

The prostate are infantile and normally developed. The unremarkable testes are descended and are within the scrotum.

**RETICULOENDOTHELIAL SYSTEM:**

The spleen weighs 9.7 grams (12 grams) and has a smooth, intact capsule covering red-purple, moderately firm parenchyma. The splenic white pulp is prominent. Lymph nodes are unremarkable. The 19.2 gram thymus (5.5 grams) is tan-pink, lobulated, and symmetrical.

**ENDOCRINE SYSTEM:**

The pituitary and thyroid glands have normal sizes, positions, and textures. The 6.6-gram combined adrenal glands (4.9 grams, combined) have unremarkable cortex and medulla.

**HEAD AND CENTRAL NERVOUS SYSTEM:**

There is no subcutaneous, subgaleal and subperiosteal hemorrhage. The external periosteum and dura mater are stripped showing no fractures of the calvarium or base of the skull. There are no tears of the dura mater. There is no epidural, subdural or subarachnoid hemorrhage.

The brain weighs 500 grams (413 grams) in the fresh state. The dura mater and falx cerebri are intact, and the leptomeninges are thin and translucent. The external examination of the brain reveals a gyral pattern consistent with the decedent's age. The structures at the base of the brain, including cranial nerves and blood vessels are intact. The brain is preserved in formalin prior to further examination.

Coronal sections of the pale brain reveal unremarkable cortical ribbon and underlying white matter. The cingulate gyri bilaterally are symmetric and firm and the adjacent corpus callosum is unremarkable. The head of caudate, putamen, globus pallidus, thalamus and anterior and posterior limbs of the internal capsule are symmetric and are without suggestion of discoloration or asymmetric softening. White matter necrosis and sequelae of intraventricular hemorrhage are not present. Hypothalamus and the mammillary bodies are likewise unremarkable. Hippocampi bilaterally reveal a normal cytoarchitectural pattern. The ventricular system is of appropriate configuration and size.

Transverse sections through the midbrain reveal symmetric peduncles and unremarkable colliculi with appropriate symmetric non pigmentation of the substantia nigra. Pons and medulla are of normal configuration and firm with typical architectural features throughout the tegmentum and the basis pontis. There is no suggestion of asymmetry or long tract demyelination. The floor of the fourth ventricle is flat.

Transverse and coronal sections of the cerebellum reveal normal dentate nuclei and unremarkable cerebellar folia.

**SPECIAL SENSES:**

The eyes are not dissected. The middle and inner ear are not dissected.

**SPINAL CORD:**

The cord is not dissected.

**EVIDENCE COLLECTION:**

No evidence collected.

**HISTOLOGIC SECTIONS:**

Representative sections from various organs are preserved in one storage jar.

**SLIDE KEY:**

1. Thymus, pancreas
2. Liver, spleen
3. Kidney and adrenal, left
4. Kidney and adrenal, right
5. Right upper lobe and right middle lobe
6. Right lower lobe
7. Left upper lobe and left lower lobe
8. Heart, left ventricle and right ventricle
- N1. Pituitary, left frontal lobe
- N2. Left basal ganglia
- N3. Left thalamus
- N4. Left hippocampus
- N5. Right hippocampus
- N6. Left occipital lobe
- N7. Midbrain
- N8. Pontomedullary junction
- N9. Medulla
- N10. Cerebellum

THYMUS (1): no significant histopathology

PANCREAS (2): no significant histopathology

LIVER (3): Residual erythropoiesis  
SPLEEN (4): No significant histopathology  
KIDNEYS (3,4): No significant histopathology.  
ADRENALS (3,4): No significant histopathology  
LUNGS (5-7): Multifocal intra-alveolar hemorrhage, mild to marked interstitial vascular congestion, and within many of the alveolar spaces are few to many foamy macrophages  
HEART (8): No significant histopathology

BRAIN (N1-N10): The leptomeninges of the cerebrum and cerebellum reveal mild vascular congestion. The cerebral cortex (frontal, temporal, occipital) has its normal laminar architecture with 6 layers. In areas, the subcortical white matter and white matter tracts are hypercellular and consists of cells with abundant eosinophilic cytoplasm and round to oval nucleus with vesicular chromatin, likely myelinating glia. Basal ganglia section shows unremarkable caudate nucleus and putamen with few clusters of residual immature neuroepithelial cells. The thalamus is unremarkable. The hippocampi and subiculum are unremarkable and are without evidence of hypoxic-ischemic neuronal change. The midbrain, pontomedullary junction and medulla are unremarkable. The cerebellum has persistent external granular cell layer, normal number of unremarkable Purkinje cells and unremarkable dentate nucleus and cerebellar white matter.

**TOXICOLOGY:**

An EDTA tube of heart blood is collected for blood typing. Samples of heart blood, liver and vitreous fluid are submitted to the laboratory. A SIDS drug panel is ordered.

**ANCILLARY STUDIES:**

Nasopharyngeal swab is sent for respiratory virus PCR panel and was negative for a viral infection.

**SPECIAL PROCEDURES:**

Anterior layer dissection and back dissection with evaluation of extremity is negative for injury.

**PHOTOGRAPHY:**

Photographs have been taken prior to and during the autopsy.



# 12

## AUTOPSY REPORT

No. 2017-07309  
YODER, BOAZ

Page 9

### **RADIOLOGY:**

Total body radiographs, 16 in total, reveal no evidence of skeletal deformity or acute and subacute injury.

### **WITNESSES:**

No witnesses were present.

### **DIAGRAMS USED:**

Diagram form #20P was used during the performance of the autopsy. Coroner diagrams are not intended to be facsimiles nor are they drawn to scale.

### **SUMMARY & OPINION:**

This 25-day-old male infant, Boaz Yoder, died of asphyxia, with methamphetamine exposure (breastfeeding) as a contributing condition.

According to investigations, Boaz was a healthy infant with no significant medical history and no recent colds. He was achieving the expected developmental milestones and was being nursed by breastfeeding. Of note, approximately a week prior, while being held by his mother in a "bobo wrap", Boaz reached out and his hand came in contact with a hot pan on top of the stove causing a burn. The mother sought out appropriate medical treatment with a pediatrician.

On October 14, 2017, Boaz was found unresponsive in his crib. Per mother, no material was on his face. Approximately five hours beforehand, he was placed on his back in his crib and numerous blankets were wrapped around his body. His mother then placed a folded quilt from a bed, weighing approximately 4-5 pounds, on top of him, to keep him warm in the cold apartment as the heater was not working properly. Emergency medical services were alerted and paramedics pronounced death.

Autopsy examination revealed a well-developed, adequately nourished male infant with pulmonary edema and congestion (increase fluid and blood in the lungs) and petechiae (pinpoint

# 12

## AUTOPSY REPORT

No. 2017-07309  
YODER, BOAZ

Page 10

hemorrhages) on the surface of the heart. There was no significant recent traumatic injury or evidence of underlying natural disease. Extended examination of the brain was unremarkable. A healing burn was noted on his left hand.


Culture of the nose did not reveal any signs of infection.

Postmortem toxicology testing performed on heart blood detected methamphetamine. As the mother was still breastfeeding the infant, it is probable that the methamphetamine was transferred from breast milk.

The circumstances surrounding Boaz's death are most consistent with asphyxia, or insufficient supply of oxygen to the body, due to compromised respiration from extensive blankets. He was found dead while sleeping with numerous blankets wrapped around him and on his chest, weighing approximately half his weight. It is probable that the excessive weight of the blankets caused compression of the chest and abdomen, leading to restriction of breathing, and causing hypoxia (decrease oxygen), cardiac arrhythmia (abnormal heart rhythm) and death.

Methamphetamine is a stimulant that may cause seizures or cardiac arrhythmias. The presence of methamphetamine would have made him more susceptible to arrhythmias.

The manner of death is accident.

  
Linda J Szymanski, D.O.  
Deputy Medical Examiner

1/23/2018  
Date

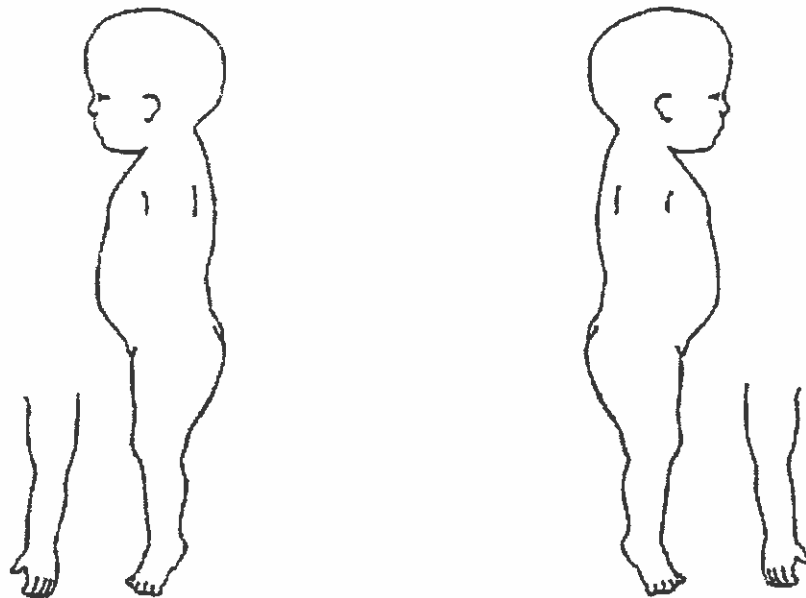
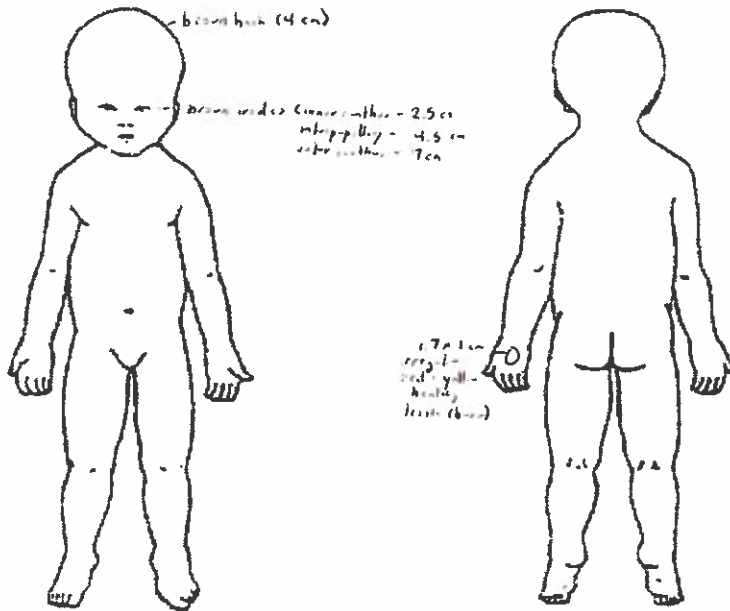
20<sub>J</sub>

Ictericity on face, chest, and back, fixed  
rigor mortis absent

2017-07309  
CORONER, BOARD  
UID

422

Crown heel - 52.5  
Head circumference - 35cm  
Chest circumference - 36cm  
Abdomen circumference - 38cm  
Weight - 4300 gm



Date 10/7/17

*[Signature]*

Deputy Medical Examiner

M.D.

# MEDICAL REPORT

DEPARTMENT OF MEDICAL EXAMINER-CORONER

COUNTY OF LOS ANGELES

AUTOPSY CLASS:  A  B  C  Examination Only D

FAMILY OBJECTION TO AUTOPSY

Date: 10/17/17 Time: 9:00 Dr. Szymanski  
(Print)

FINAL ON: \_\_\_\_\_ By: \_\_\_\_\_  
(Print)

APPROXIMATE INTERVAL BETWEEN ONSET AND DEATH

2017-07309

YODER, BOAZ

UNO

422

# 15

DEATH WAS CAUSED BY: (Enter only one cause per line for A, B, C, and D)

IMMEDIATE CAUSE:

(A) Asphyxia

Unk

Age: 25 dy, Gender: Male / Female

DUE TO, OR AS A CONSEQUENCE OF:

(B)

### PRIOR EXAMINATION REVIEW BY DME

- BODY TAG  CLOTHING
- X-RAY (No. \_\_\_\_\_)  FLUORO
- SPECIAL PROCESSING TAG  MED. RECORDS
- AT SCENE PHOTOS (No. \_\_\_\_\_)

DUE TO, OR AS A CONSEQUENCE OF:

(C)

### CASE CIRCUMSTANCES

DUE TO, OR AS A CONSEQUENCE OF:

(D)

- EMBALMED
- DECOMPOSED
- >24 HRS IN HOSPITAL
- OTHER: Field (Reason)

OTHER CONDITIONS CONTRIBUTING BUT NOT RELATED TO THE IMMEDIATE CAUSE OF DEATH:

Methamphetamine exposure (breastfeeding)

### TYPING SPECIMEN

TYPING SPECIMEN TAKEN BY: Szymanski

SOURCE: Heart blood

### TOXICOLOGY SPECIMEN

COLLECTED BY: Szymanski

- HEART BLOOD  STOMACH CONTENTS
- FEMORAL BLOOD  VITREOUS

TECHNIQUE

- BLOOD  SPLEEN
- BLOOD  KIDNEY
- BILE
- LIVER
- URINE

URINE GLUCOSE DIPSTICK RESULT: 4+ 3+ 2+ 1+ 0

TOX SPECIMEN RECONCILIATION BY: [Signature]

### HISTOLOGY

- Regular (No. 1)  Oversize (No. 1)
- Histopath Cut:  Autopsy  Lab

### TOXICOLOGY REQUESTS

- FORM 3A:  YES  NO
- NO TOXICOLOGY REQUESTED
  - SCREEN  C  H  T  S  D
  - ALCOHOL ONLY
  - CARBON MONOXIDE
  - OTHER (Specify drug and tissue)

### REQUESTED MATERIAL ON PENDING CASES

- POLICE REPORT  MED HISTORY
- TOX FOR COD  HISTOLOGY
- TOX FOR R/O  INVESTIGATIONS
- MICROBIOLOGY  EYE PATH. CONS.
- RADIOLOGY CONS.
- CONSULT ON: \_\_\_\_\_
- BRAIN SUBMITTED
- NEURO CONSULT  DME TO CUT
- CRIMINALISTICS
- GSR  SEXUAL ASSAULT  OTHER

NATURAL  SUICIDE  HOMICIDE

ACCIDENT  COULD NOT BE DETERMINED

Discussed with Dr. Lucas  
If other than natural causes,  
HOW DID INJURY OCCUR? Heavy blanket (4-5 pounds) placed on <sup>est. head</sup> <sup>top of</sup> neck  
CR 1-4-18

WAS OPERATION PERFORMED FOR ANY CONDITION STATED ABOVE:  YES  NO

TYPE OF SURGERY: \_\_\_\_\_ DATE: \_\_\_\_\_

ORGAN PROCUREMENT  TECHNICIAN: D. Dominguez

PREGNANCY IN LAST YEAR  YES  NO  UNK  NOT APPLICABLE

WITNESS TO AUTOPSY  EVIDENCE RECOVERED AT AUTOPSY  
Item Description: \_\_\_\_\_

Case reviewed with Dr. Szymanski. OK for undetermined manner.

CR 1-4-18

RESIDENT

DME

16

2017-07309

YODER, BOAZ

UND

422

EXTERNAL EXAM

Sex
Race
Age
Height
Weight
Hair
Eyes
Sclera
Teeth
Mouth
Tongue
Nose
Chest
Breasts
Abdomen
Scar
Genitals
Edema
Skin
Decubitus

HEART Wt. 22.9

epicardial pectchen near left atrial appendage between aorta & left atrial appendage

Pericardium RV 0.3
Hypertrophy Septum 0.7
Dilation LV 0.5
Muscle Septum
Valves
Coronaries

TV = 3.5, PV = 2.5,
MV = 3.5, AV = 2.5

AORTA

VESSELS

LUNGS Wt.

R 64.7
L 55.9
Adhesions
Fluid
Atelectasis
Oedema
Congestion +
Consolidation
Bronchi - pink fluid in airways
Nodes

PHARYNX

TRACHEA

THYROID

THYMUS 19.2

LARYNX

HYOID

ABDOMINAL WALL FAT

PERITONEUM

Fluid
Adhesions

LIVER Wt. 112

Capsule
Lobules
Fibros
G B
Calculus
Bile ducts

SPLEEN Wt. 9.7

Color
Consistency
Capsule
Malpignent

PANCREAS

ADRENALS RA = 3.2, LA = 3.4

KIDNEYS Wt.

R 10.6
L 10
Capsule

Cortex
Vessels
Pelvis
Ureters

BLADDER No urine

GENITALIA

Prostate +
Testes +
Uterus
Tubes
Ovaries

OESOPHAGUS

STOMACH 25.6 of milk noted

Contents

DUOD. & SM. INT.

APPENDIX +

LARGE INT. dilatation of blind

ABDOM. NODES

SKELETON

Spine
Marrow
Rib Cage
Long bones
Pelvis

SCALP

CALVARIUM

BRAIN Wt. 500

Dura
Fluid
Ventricles
Vessels
Middle ears
Other

PITUITARY +

SPINAL CORD

TOXICOLOGY SPECIMENS

Liver, heart blood, urine

SECTIONS FOR

HISTOPATHOLOGY

- 1. Thyroid, pancreas 5. RU + RL
2. Liver, spleen 6. RU
3. L Kidney, adrenal 7. LUL + LML
4. R Kidney, adrenal 8. Heart

MICROBIOLOGY

Nosepharynx

DIAGRAMS 20

X-RAYS

OTHER PROCEDURES

GROSS IMPRESSIONS

Date

Time

Deputy Medical Examiner

10/7/17

9:00

[Signature]



Department of Medical Examiner-Coroner, County of Los Angeles

# FORENSIC SCIENCE LABORATORIES

1104 North Mission Road Los Angeles, CA 90033



## Laboratory Analysis Summary Report

Szymanski, Linda O.D.

Deputy Medical Examiner  
1104 North Mission Road  
Los Angeles, CA 90033

PendingTox

The following results have been technically and administratively reviewed and are the opinions and conclusions of the Analyst:

**Coroner Case Number:** 2017-07309 **Decedent:** YODER, BOAS

<u>SPECIMEN</u>	<u>SERVICE</u>	<u>DRUG</u>	<u>RESULT</u>	<u>ANALYST</u>
<b>Blood, Heart</b>				
	Alcohol-GC/FID-HS	Ethanol	Negative	E. Fu
	Bases-GC/NPD &/or MS	Basic Drugs	ND	R. Cabrera
	ELISA-Immunoassay	Acetaminophen	ND	D. P. Cruz
	ELISA-Immunoassay	Barbiturates	ND	R. Cabrera
	ELISA-Immunoassay	Cocaine and Metabolites	ND	R. Cabrera
	ELISA-Immunoassay	Marijuana: 11-nor-Delta-9-Carboxy-THC	ND	R. Cabrera
	ELISA-Immunoassay	Methamphetamine & MDMA	PP	R. Cabrera
	ELISA-Immunoassay	Opiates: Codeine & Morphine	ND	R. Cabrera
	ELISA-Immunoassay	Opiates: Hydrocodone & Hydromorphone	ND	R. Cabrera
	ELISA-Immunoassay	Phencyclidine	ND	R. Cabrera
	ELISA-Immunoassay	Salicylate	ND	D. P. Cruz
	Sympath. Amines-GC/MS	Amphetamine	ND	D. Levanas
	Sympath. Amines-GC/MS	Methamphetamine	0.05 ug/mL	D. Levanas
	Sympath. Amines-GC/MS	Methylenedioxyamphetamine (MDA)	ND	D. Levanas
	Sympath. Amines-GC/MS	Methylenedioxymethamphetamine (MDMA)	ND	D. Levanas
	Volatiles-GC/FID-HS	Acetone	ND	E. Fu
	Volatiles-GC/FID-HS	Isopropanol	ND	E. Fu
<b>EDTA Heart Blood</b>				
	Sympath. Amines-GC/MS	Amphetamine	ND	D. Levanas
	Sympath. Amines-GC/MS	Methamphetamine	QNS	D. Levanas

*JKR*  
12.20.17  
*HJH* 12-22-17

Coroner Case Number: 2017-07309 Decedent: YODER, BOAS

SPECIMEN   SERVICE                      DRUG    RESULT                      ANALYST

<b>Legend:</b>		mg/dL	Milligram per Deciliter	PP	Presumptive Positive
g	Grams	mg/L	Milligram per Liter	QNS	Quantity Not Sufficient
g%	Gram Percent	ND	Not Detected	ug	Micrograms
Inc.	Inconclusive	ng/g	Nanograms per Gram	ug/g	Micrograms per Gram
mg	Milligrams	ng/mL	Nanograms per Milliliter	ug/mL	Microgram per Milliliter

In accordance with the Department's Evidence Retention Policy, the blood specimen(s) will be retained for one-year and all other specimens for six-months from Autopsy.

Administratively reviewed by: 

**Eric J. Wahoske**  
Supervising Criminalist  
(323) 343-0530 ewahoske@coroner.lacounty.gov

JKB  
12.20.17

Szym A. K.

COUNTY OF LOS ANGELES

CASE REPORT


DEPARTMENT OF CORONER

1	APPARENT MODE <b>UNDETERMINED</b>	CASE NO 2017-07309
	SPECIAL CIRCUMSTANCES	CRYPT 422

LAST, FIRST MIDDLE <b>YODER, BOAS</b>	AKA	#
--	-----	---

ADDRESS <b>844 ALAMADA STREET</b>	CITY <b>ALTADENA</b>	STATE <b>CA</b>	ZIP <b>91001</b>
SEX <b>MALE</b>	RACE APPEARS <b>CAUCASIAN</b>	DOB <b>9/10/2017</b>	AGE <b>25 D</b>
HGT <b>20 in.</b>	WGT <b>10 lbs.</b>	EYES <b>BROWN</b>	HAIR <b>BROWN</b>
TEETH <b>ALL NATURAL TEETH</b>	FACIAL HAIR <b>MUSTACHE</b>	ID VIEW <b>Yes</b>	CONDITION <b>FAIR</b>

MARK TYPE	MARK LOCATION	MARK DESCRIPTION
		<b>NONE OBSERVED</b>



SSN	DL ID	STATE	PENDING BY
-----	-------	-------	------------

ID METHOD <b>VISUALLY AT SCENE</b>
---------------------------------------

LA #	MAIN #	CI #	FBI #	MILITARY #	POB
------	--------	------	-------	------------	-----



PLACE OF DEATH / PLACE FOUND <b>RESIDENCE</b>	ADDRESS OR LOCATION <b>844 ALAMADA STREET</b>	CITY <b>ALTADENA</b>	ZIP <b>91001</b>
--	--	-------------------------	---------------------

PLACE OF INJURY <b>RESIDENCE</b>	AT WORK <b>No</b>	DATE <b>10/5/2017</b>	TIME	LOCATION OR ADDRESS <b>844 ALAMADA STREET, ALTADENA, CA</b>	ZIP <b>91001</b>
-------------------------------------	----------------------	--------------------------	------	--	---------------------

DOD <b>10/5/2017</b>	TIME <b>07:44</b>	FOUND OR PRONOUNCED BY <b>LA CO FD</b>
-------------------------	----------------------	---

OTHER AGENCY INV. OFFICER <b>LASD HOMICIDE - DET. MORSE</b>	PHONE <b>(323) 890-5500</b>	REPORT NO. <b>017-02844-0774496</b>	NOTIFIED BY <b>NO</b>
--	--------------------------------	--	--------------------------

TRANSPORTED BY <b>BRENDA SHAFER</b>	TO <b>LOS ANGELES FSC</b>	DATE <b>10/5/2017</b>	TIME <b>11:50</b>
--	------------------------------	--------------------------	----------------------

FINGERPRINTS? <b>No</b>	CLOTHING <b>Yes</b>	PA RPT <b>No</b>	MORTUARY
MED. EV. <b>No</b>	INVEST. PHOTO # <b>23</b>	SEAL TYPE	HOSP RPT <b>No</b>
PHYS. EV. <b>No</b>	EVIDENCE LOG <b>No</b>	PROPERTY? <b>No</b>	HOSP CHART <b>No</b>
SUICIDE NOTE <b>No</b>	GSR NO	RCPT NO.	PF NO

SYNOPSIS  
The infant's mother nursed him sometime after 0200 hours and laid him supine in his crib. Because the heater in the home was not coming on, she laid blankets on him to keep him warm. When he still felt cool to the touch she folded a queen sized quilt (weighing an estimated 4-5 pounds) and laid it on top of him to his neck - not covering his face. She woke just before 0730 hours and found him unresponsive. Paramedics determined death on scene. The infant was full term, no medical history, no recent cold symptoms.

BRENDA SHAFER 459893		INVESTIGATOR	DATE <b>10/6/2017</b>	REVIEWED BY 	DATE <b>11:36</b>
-------------------------	--	--------------	--------------------------	-----------------	----------------------

FORM #3 NARRATIVE TO FOLLOW?





County of Los Angeles, Department of Coroner  
Investigator's Narrative



Case Number: 2017-07309

Decedent: YODER, BOAS

**Information Sources:**

Decedent's Mother.

On-Scene Investigation.

**Investigation:**

On 10/05/17 at 0806 hours Security Fernandez reported this case to our office. The scene was ready for my response and I was assigned this field call at 0920 hours. I arrived on scene at 1000 hours and concluded my scene investigation at 1120 hours and I arranged for the transportation of the body to the Forensic Science Center.

**Location:**

Injury (possible) and death occurred at the decedent's residence located at 844 Alameda Street in Altadena.

**Informant/Witness Statements:**

**Pregnancy/Birth:** Boas was born vaginally full term (40 weeks 5 days) on 09/10/17 at Good Samaritan Hospital weighing 8 pounds 5 ounces, 19 inches long with the aid of a vacuum. The mother reports that there were no complications during the pregnancy and that she was not prescribed any medications during the pregnancy and didn't take any on her own. However, she did use vape with zero/or trace amounts of nicotine.

**Nursing/Progress:** Boas is nursing only and doing so every 2 hours, not going more than 3 hours between feedings. He saw his pediatrician once, gained a pound, appeared to be healthy and meeting the appropriate milestones. He was not constipated and was wetting and soiling diapers as expected. He was not colicky and rarely spit up. Mother vapes using 3% nicotine.

**Burn on hand:** According to the mother she is practicing attachment parents and "wearing" Boas. In doing so on 09/28/17 she had him strapped to the front of her body with his arms out and his hand came in contact with a hot pan. She brought him to the pediatrician on 09/29/17 to have the hand looked at. He has had no recent cold symptoms, no congestion, no excessive mucous, and no coughing.

According to the mother on 10/04/17 she and Boas returned home at 2000 hours. The house was cold and she turned on the heat. She'd initially planned to leave again to go to her in-laws house in Sherman Oaks but it was late and the infant was tired so she decided to stay in Altadena for the night. She heat would not come on and she kept checking it but it felt like the air conditioner was on instead. She put on extra clothing and put the infant in a Onesie and put socks on his feet and hands. She then wrapped him in 2 muslin blankets leaving his arms out. She placed him in his crib on a contoured changing pad, swaddled him in a woolen blanket – leaving his arms out and then placing a small square croquet blanket on top this time on top of the arms as well.

She last checked on him at 0200 hours and nursed him soon after that. She placed him on his back on the contoured pad, wrapped him as before, replacing all the previous blankets. However, still not able to get the heater to work and herself still feeling that the room was cold, she took a quilt from a bed, folded it and placed it on top of the infant covering the arms – estimated by Detective Morse to weigh between 4-5 pounds. She woke at 0729 hours and found the infant unresponsive, with nothing occluding his face, cool to the touch but otherwise appeared normal. She 1<sup>st</sup> called the infants father and asked him what to do because she didn't know CPR and thought that there was something that she could do to revive him. He advised her to check for breathing with a mirror. When she could not see breaths, he advised her to call 911 which she did at 0730 hours.

(B)



County of Los Angeles, Department of Coroner  
Investigator's Narrative



Case Number: 2017-07309

Decedent: YODER, BOAS

**Scene Description:**

The scene is a 2-bedroom residence that is part of a duplex. The residence is neat however contains numerous animals that include a large dog and caged birds. The infant is immediately seen on the living room sofa where the paramedics have reportedly moved him during rescue efforts after finding him unresponsive in his crib.

The crib is in one of the bedrooms that contains a crib, a twin bed, changing table, and various new and modern infant accessories such as a vaporizer and an air purifier. A contoured pad was inside the crib where the mother reports she laid the infant. The blankets she described are in the crib, on the floor, and on the nearby twin bed. The muslin blankets were very light, the woolen blanket was approximately a 1/2 pound, the croquet blanket the same, and the gray quilt was a queen size - folded was between 4-5 pounds.

**Evidence:**

Evidence was not collected or warranted in this case.

**Body Examination:**

The body was observed to be that of a male infant of the reported age of 25 days. He is uncircumcised, wearing a blue/white Onesie, blue/white socks, and a soiled diaper. Lividity on the back is consistent with the supine position, as reported that ended at the diaper line. However, I immediately noticed that the lividity on the abdomen was not. The chest exhibits red/purple lividity in a half circle that is absent on the abdomen which may be consistent with something putting pressure on the abdomen. The legs showed lividity that ended at the sock line. The face had dark splotchy lividity throughout. Rigor mortis was full throughout the body as expected. The eyes were dark and the hair brown.

**Identification:**

██████████ viewed the infant at scene and confirmed identification.

**Next of Kin Notification:**

██████████ was present at scene and aware of the death of her son.

**Autopsy Notification:**

There were no requests for autopsy notification.

  
BRENDA SHAFER

  
DAVID SMITH

10/03/2017

Date of Report

6B

WAS ORIGINAL SCENE DISTURBED BY OTHERS?  
IF YES, NOTE CHANGES IN NARRATIVE FORM #3.

Y  N

2017-07309  
Yoder, Boos  
THERMOMETER # \_\_\_\_\_

DATE \_\_\_\_\_  
AMBIENT #1 \_\_\_\_\_ °F TIME \_\_\_\_\_  
AMBIENT #2 \_\_\_\_\_ °F TIME \_\_\_\_\_  
WATER \_\_\_\_\_ °F TIME \_\_\_\_\_

DATE & TIME FOUND 10/5/17 0729 LAST KNOWN ALIVE 0700  
APPROX. AGE 280 SEX M CLOTHED? YES  NO  IF YES, DESCRIBE:  
see narrative

DESCRIPTION AS TO WHERE REMAINS FOUND AND CONTACT MATERIAL TO BODY:  
apine - see narrative

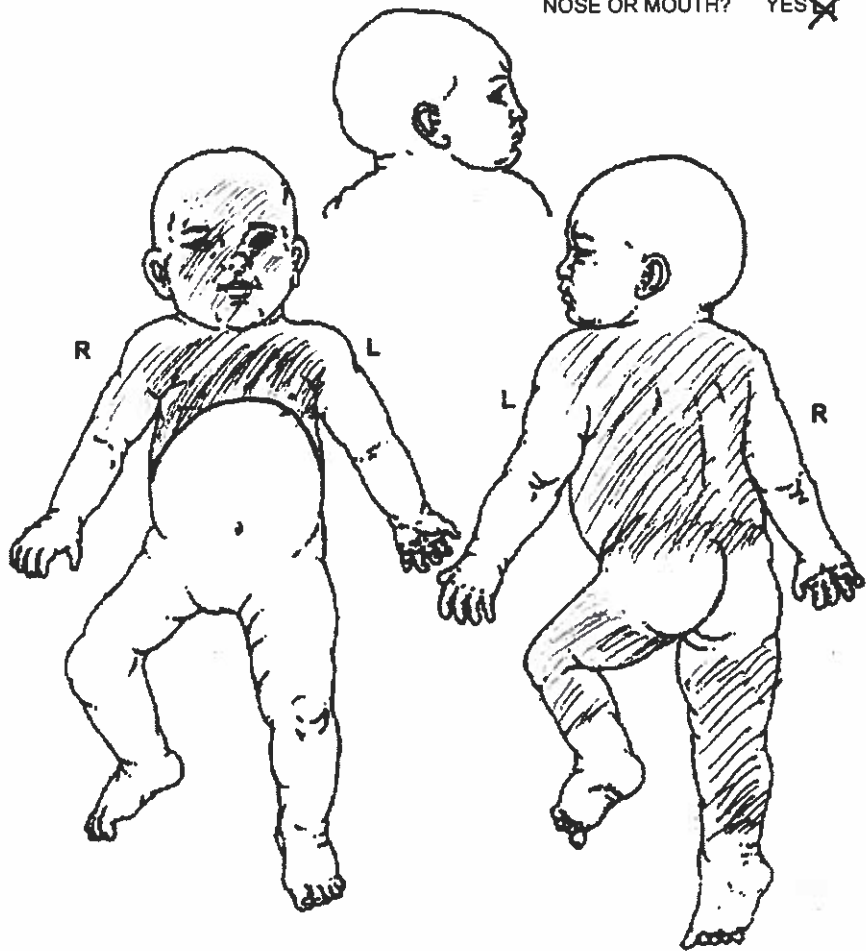
SCENE TEMPERATURE REGULATED? YES  NO  IF YES, THERMOSTAT SET AT \_\_\_\_\_ DEGREES F.

PETECHIAE OF EYES? YES  NO  ?  
OF FACE? YES  NO  ?  
\* IF PRESENT, TAKE CLOSEUP PHOTOS

RIGOR MORTIS: TIME OBSERVED \_\_\_\_\_  
NECK FLEXION:  
ANTERIOR \_\_\_\_\_  
POSTERIOR \_\_\_\_\_  
RT. LATERAL \_\_\_\_\_  
T. LATERAL \_\_\_\_\_

BLOOD OR DARK FLUID IN  
NOSE OR MOUTH? YES  NO

JAW \_\_\_\_\_ HIP \_\_\_\_\_  
SHOULDER \_\_\_\_\_ KNEE \_\_\_\_\_  
ELBOW 4-full ANKLE \_\_\_\_\_  
WRIST \_\_\_\_\_



SCALE  
0 = ABSENT/NEGATIVE  
1 +  
2 +  
3 +  
4 = EXTREME DEGREE

USE SCALE TO DESCRIBE INTENSITY OF RIGOR MORTIS.

LIVOR MORTIS: TIME OBSERVED \_\_\_\_\_

SHADE DIAGRAMS TO ILLUSTRATE THE LOCATION OF LIVOR MORTIS.

DESCRIBE INTENSITY OF COLORATION AND WHETHER LIVOR MORTIS IS PERMANENT OR BLANCHES UNDER PRESSURE.

[Signature]  
CORONER'S INVESTIGATOR

REVIEWED BY: